

Heart conditions

by MaryDee Sist, DVM

*Originally published in Baraka Book,
Autumn-Winter 2001*

For the last decade I have been involved in Saluki heart research. Our original goal was to examine the incidence of cardiomyopathy. When characterizing Saluki hearts through physical examinations, electrocardiograms and ultrasonography, we discovered that there were differences from what was accepted as “normal” in mixed-breed populations. To know if these changes were significant or were just unique to Salukis we had to continue to examine these dogs as they aged and after death to see if any of these changes resulted in heart disease.

Saluki fanciers want to know what heart diseases occur and if any of the conditions could be inherited or genetic. Our pathology study is documenting what heart conditions occur in Salukis. But determining if these are significant diseases that could be inherited or genetic is very difficult. Some heart conditions are thought to be inherited in certain breeds because the condition occurs at a greater incidence than in mixed breed populations. And some conditions seem to be prevalent in certain families. However, is it fair to generalize from what is found in other breeds to salukis? Pedigree studies need to be done on affected dogs and their relatives to determine the possible inheritance.

Heart conditions can be classified in two major groups, congenital or acquired. Congenital conditions, or defects that the dog was born with, are abnormalities in the structure of the heart, heart valves, or the major vessels. These might or might not be genetic. They typically cause problems or symptoms early in the dog’s life, such as inactivity or poor growth and a heart

murmur. Congenital heart diseases that are known to have a polygenic mode of inheritance in the following breeds are: Patent ductus arteriosus (PDA) in poodles, Aortic stenosis (AS) or narrowing of the valve in Newfoundlands, and Pulmonic stenosis (PS) in beagles.

Acquired heart conditions develop due to disease states or degenerative conditions that occur as the dog ages. The dog is born with a normal functioning heart, but changes occur with time and affect either the fibrous sac enclosing the heart, the pericardium (PERICARDIAL DISEASE) or the heart muscle itself, (PRIMARY MYOCARDIAL DISEASE) or the heart valves (VALVULAR DISEASE).

PERICARDIAL DISEASE is the least commonly encountered. It generally involves the accumulation of fluid in the sac around the heart. Heart sounds are often muffled due to the fluid accumulation. The heart looks huge on a radiograph and an echocardiogram is needed to determine if it is fluid around the heart or if the heart is enlarged. This fluid or pericardial effusion impairs the ability of the heart to fill properly with blood. As a result fluid builds up in the lungs or abdominal cavity causing signs of heart failure since the heart can’t pump the blood through the body properly. Usually a mass on the surface of the heart or, much less commonly, thickening in the pericardium due to infection causes the fluid build up. In older dogs, cancer (usually hemangiosarcoma) in the heart is the most common cause and rupture of the mass causes bleeding into the sac and the dog collapses.

PRIMARY MYOCARDIAL DISEASE occurs when the heart muscle weakens and fails as a pump. Early on there are no symptoms as the heart compensates for its loss of contractility by enlarging. But

eventually, the failure of the heart to pump enough blood results in accumulation of fluid in the body and signs of heart failure. Dilated cardiomyopathy (DCM), where the heart muscle wall thins out, is more commonly seen than where the muscle wall thickens (hypertrophic cardiomyopathy). A hereditary nature is suspected since DCM affects certain, generally large breeds of dogs, and expresses itself differently in different breeds. Giant breeds most often show congestive heart failure signs with fluid accumulation in the lungs. While in Boxers, the major abnormality is in the electrical conduction system of the heart. This causes an irregular heart rhythm and can result in fainting or syncopal episodes which makes the dog prone to sudden death. The condition is diagnosed on an echocardiograph by finding enlargement of the chambers of the heart and poor contractility. HOWEVER, other heart conditions can cause some secondary enlargement of the chambers and alteration of contractility, but these are not primary diseases of the heart muscle like DCM.

VALVULAR DISEASE occurs when any of the four valves that regulate the direction and amount of blood flow through and out of the heart don’t function properly. The AV valves separate the upper chambers (atri) from the lower pumping chambers (ventricles) on the right (mitral) and left (tricuspid) sides of the heart. The pulmonary valve regulates the blood flowing in the artery to the lungs and the aortic valve, blood flowing to the body. Since the valve doesn’t close completely, blood spills back (regurgitation) across the leaky (insufficient) valve and a murmur from turbulent blood flow is heard. Over time this back flow of blood causes the heart



muscle to have to work harder to move the same volume of blood. The muscle thickens and the heart enlarges. Eventually, signs of heart failure will develop as fluid builds up in the lungs or body (volume overload). This is the most common group of heart conditions and can occur from a variety of causes.

Valvular disease can be a congenital condition, generally termed dysplasia, because there is some defect that makes the valves not fit and close properly. There can be infectious causes where bacteria colonize on the valve causing vegetations or nodules to form (termed 'itis'). With age, degeneration (termed 'osis') of the valves can also occur where the leaflets thicken and develop nodular swellings that coalesce. With time this results in more leakage which causes more changes in the valves. In some dogs, this volume overload is well tolerated, whereas in other dogs there is a rapid progression to congestive heart failure.

Bacterial infections usually affect the aortic and mitral valves causing valvular endocarditis. Degenerative changes commonly affect the AV valves causing valvular endocardiosis. The left AV or mitral valve is more frequently involved and as the insufficiency progresses, eventually fluid will build up in the lungs. Less commonly, regurgitation of the tricuspid or right AV valve will result in fluid building up in the abdomen (ascites).

Early on, dogs with valvular endocardiosis have no outward signs, but a murmur can be heard by a veterinarian. The point of maximum intensity (PMI) or location of the murmur can indicate what valve is leaking. The loudness of the murmur (graded on a scale of I to VI) doesn't necessarily indicate the severity of the leak of blood across the valve. The definitive identification of valvular conditions requires a cardiac ultrasound with a

Doppler exam to quantify the direction, volume, and velocity or severity of the regurgitant blood flow.

Mitral degeneration, or valvular endocardiosis (also termed verrucous or myxomatous degeneration of the valvular endocardium) is common in small breeds of dogs as they age. It is not thought to routinely occur in large breeds. However, a large number of the Salukis examined had varying degrees of mitral valve disease. In some dogs, this insufficiency was well tolerated. In others, it progressed to congestive heart failure. Pedigree analyses of affected and related dogs need to be conducted to

help determine if this could have a heritable component.

Congenital heart defects generally cause clinical signs in young dogs. However acquired heart conditions develop as a dog ages. Without routine physical examinations, these will not be detected unless the dog has progressed to a severity of disease where signs of heart failure become apparent. Murmurs detected on physical examination are often early indicators of heart problems and necessitate further evaluation. Often, this requires repeated examinations as the dog ages to see if the heart condition progresses.

Saluki heart pathology study

by MaryDee Sist, DVM

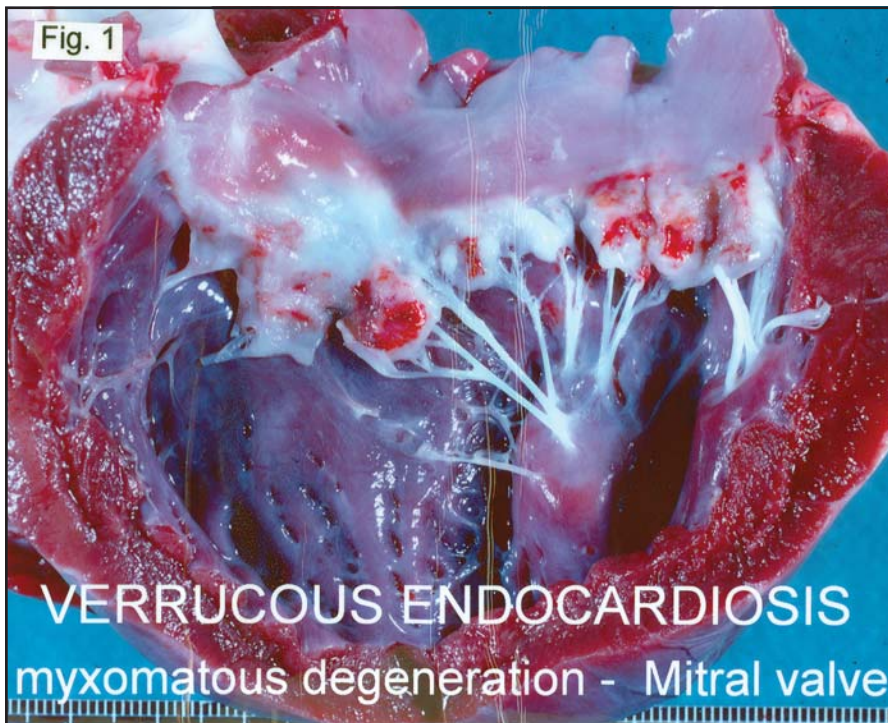
Originally published in Baraka Book, 2002

There has been debate regarding the incidence, importance and types of cardiac disease found in Salukis. Dr. Cathy Gaber, a board certified cardiologist, has evaluated 100 Salukis from one to six times over a 6 year period in the Saluki Heart Study that I initiated in 1990. The goal was to characterize the normal Saluki heart through auscultation, electrocardiogram and ultrasonographic evaluation. However, many Salukis when compared to mixed breeds, had changes that could be associated with heart disease.

Over a third of the Salukis examined had a heart murmur on auscultation, due to abnormal blood flow across a heart valve. Most were soft murmurs and the dogs remained free of signs of heart disease. Some had arrhythmias, or an irregular heart rhythm and/or rate on the ECG recording. Many of the Salukis had enlarged hearts, especially the left ventricles, when compared with other breeds of similar body size. Also, some

had decreased contractility (%FS) of the heart muscle during the echo examination. Each of these are changes that can be associated with significant heart diseases as well as dilated cardiomyopathy.

As a result, a post-mortem study of the hearts was begun in 1997 to try to determine if the changes seen in the cardiovascular examinations of the salukis were significant to their health, especially as the dogs aged. Dr. Thomas Bell, a pathologist at the Animal Health Diagnostic Laboratory at Michigan State University was recruited to perform gross, macro and microscopic evaluations of Saluki hearts. He found a surprising array of pathological changes in the Salukis while very few had developed clinical signs of heart disease. This led to further investigations of Salukis that died suddenly or had various forms of cancer. To date 96 (40 males, 8 castrated males, 24 females and 24 spayed females ranging from 7 months to nearly 16 years of age) Saluki hearts have been examined.



The most prevalent finding was myxomatous degeneration of the valvular endocardium, also known as verrucous endocardiosis of the left AV or mitral valve (Fig. 1). These nodular thickenings stop the valve from closing properly and the valve becomes insufficient or leaks. This change was found in 52% (50/96) of the hearts, but the lesions were of sufficient severity to

cause the demise of only half of the dogs with mitral insufficiency. Five Salukis died of congenital heart valve defects. Fig. 2 shows a hole in the tricuspid valve where there is only a single cusp instead of three. Only two died of primary Dilated Cardiomyopathy, which was definitively diagnosed by microscopically finding the characteristic “wavy” cardiac

myofibers (Fig. 3) and large heart size.

The next most common cause of death was a rare type of vascular cancer, Hemangiosarcoma, which was found in 25% (24/96) of the Salukis. Fig. 4 shows a ruptured hemangiosarcoma tumor in the atrial appendage and a small metastasis growing out of the epicardial surface of the ventricle. The right atrial appendage of the heart was the most common primary site. However, the most disconcerting finding was that 52% (50/96) of the Salukis had one or more forms of cancer contributing to their demise.

Another unexpected finding was the incidence in 47% (45/96) of some form of acquired heart vessel changes, most commonly arteriosclerosis or a narrowing of the small arteries due to connective tissue deposition in the wall (Fig. 5). Less commonly arterio- and atherosclerotic (fatty) changes were also found. As is the case in most dogs, only a small number of Salukis had infarcts or ischemic areas in the heart muscle (Fig. 6) due to these vessel changes. Any of these vascular changes that affect the blood supply to the heart muscle can lead to heart attacks in humans.

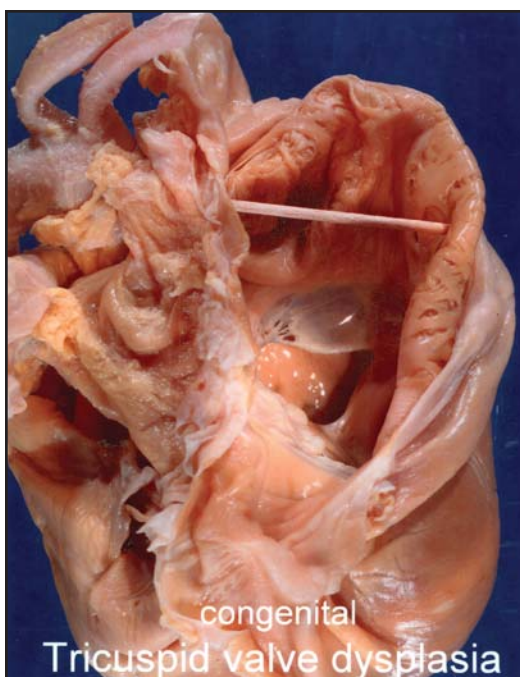


Fig.2

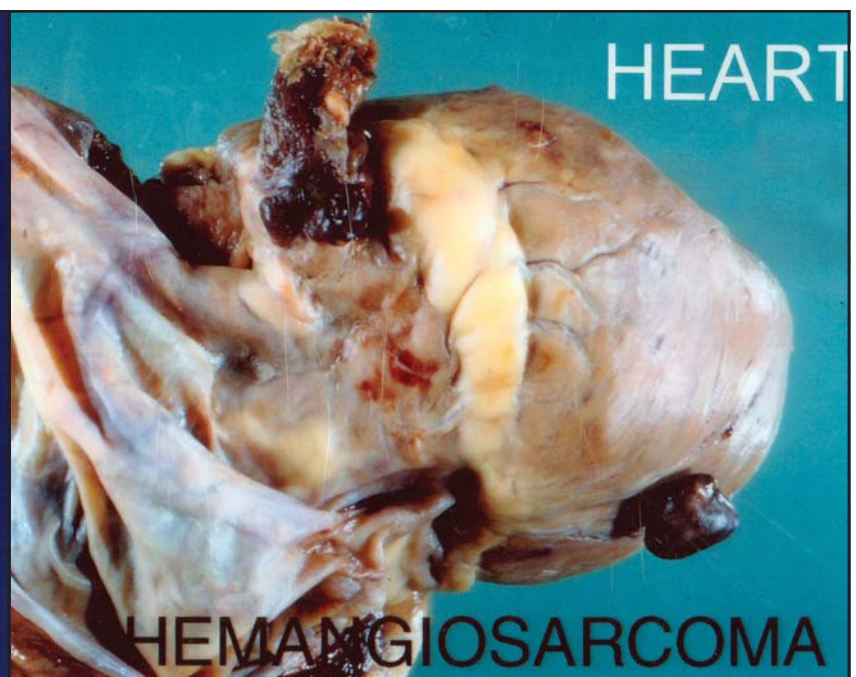

Fig.4

Fig. 3 normal heart muscle

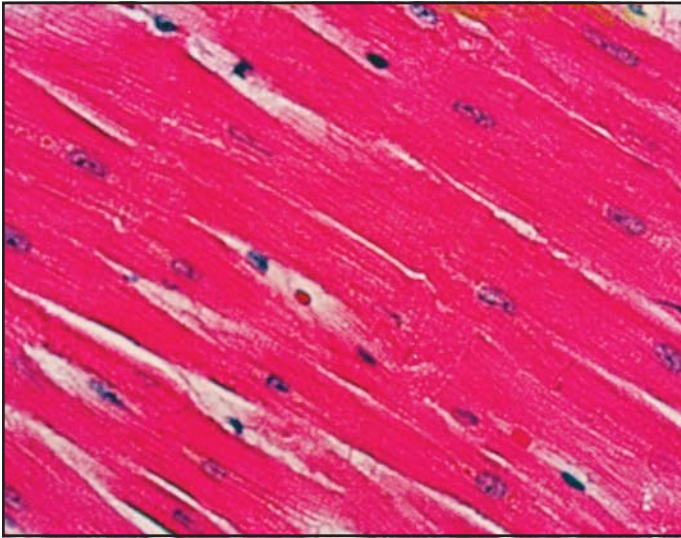
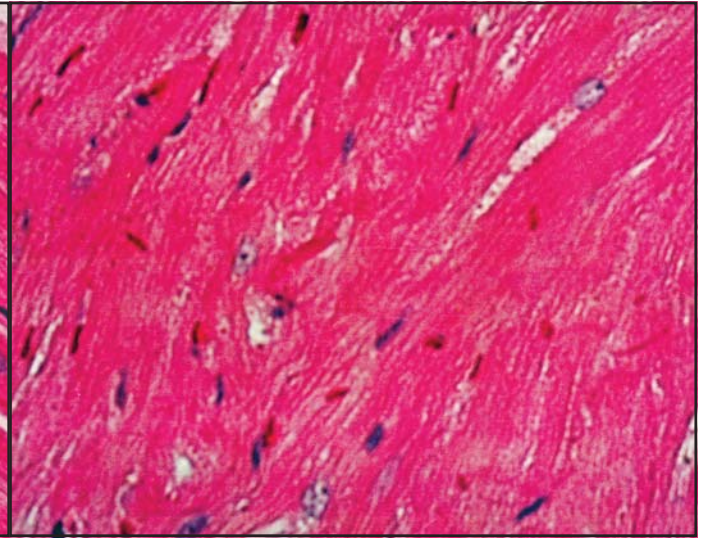


Fig. 3 abnormal heart muscle



However, in dogs, due to their abundant collateral circulation, this rarely causes symptoms and only one dog had significant myocardial degeneration due to the blockage of the small arteries.

The pathology study was initiated to examine the hearts of "normal" Salukis' however, some dogs did develop heart-related signs. Chronic or long term heart failure signs developed in 13 dogs and they died at an average age of 8.6 years. These chronic heart disease signs included difficulty breathing, coughing, inappetence and weakness. Over half of these dogs died as a result of verrucous endocarditis of the mitral (left AV) valve. Their hearts had failed to pump adequate amounts of blood due to leakage across the mitral valve and compensated by becoming quite large (average heart weight was 334 grams, about a third larger than hearts without any pathology) (Fig. 7). Seven additional dogs had acute (less than two days) signs of heart failure and died at an average age of 10.6 years. Half of these died of hemangiosarcoma in the right atrial appendage of the heart.

A second group included dogs euthanized for reasons that were unrelated to symptoms of heart

conditions. Most of the hearts examined were from older dogs showing signs of failing health. These dogs averaged 12.75 years of age at death and 50% had verrucous endocardial changes of the left AV valve or mitral insufficiency. Their hearts, however, were not as large as the chronic heart failure group discussed above. 80% had some form of cancer. Fig. 8 shows hemangiosarcoma tumors in the heart, spleen, liver and seeded throughout the abdominal cavity. Of the dogs euthanized at an average of 11 years without signs of failing health, most had mild verrucous endocarditis, but their hearts were judged to be normal for their age and were not enlarged (average heart weight 230 grams).

The last group consisted of 24 dogs that died suddenly at an average age of 7.5 years. The hearts of two of these dogs showed no pathology. 50% (12/24) died of hemangiosarcoma and 25% (6/24) died of a suspected arrhythmia due to Purkinje fiber degeneration. Fig. 9 shows degeneration and vacuoles or holes where Purkinje fibers should be. This degeneration caused an electrical conduction disturbance in the heart. Two died from

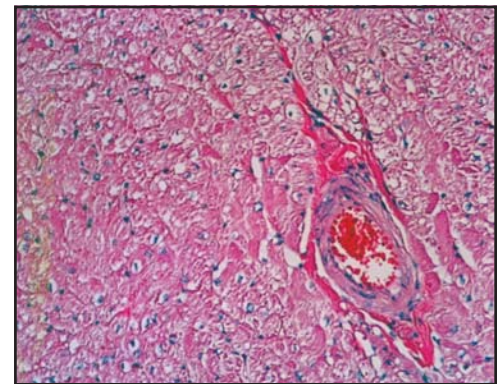


Fig. 5 normal arteriole

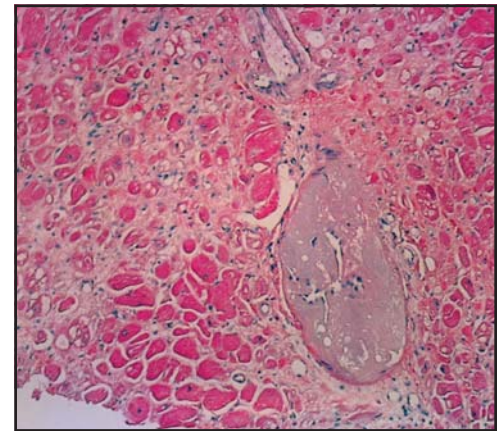


Fig. 5 arteriosclerosis (narrowed arteriole)

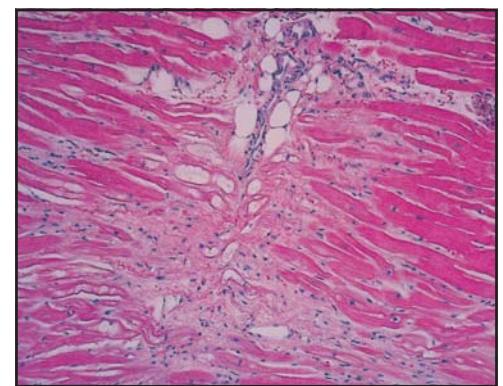


Fig. 6 arteriosclerosis resulting in ischemia (lack of normal blood flow) and infarction (atrophy, necrosis, fibrosis and vacuolization of the heart muscle fibers)

myocarditis or an infection affecting the heart, and two from congenital valvular heart defects.

In conclusion, the examination of Saluki hearts in this study showed that:

- A surprising array of heart pathology was found in symptom-free dogs.
- Myxomatous degeneration of the valvular endocardium of the left AV (mitral) valve or MITRAL INSUFFICIENCY was the most common heart problem and the heart showed compensatory enlargement or dilation as the condition progressed over time. Clinically in these dogs, a heart murmur should be heard when examined prior to death.
- A dilated heart does not necessarily mean a diagnosis of cardiomyopathy.

- Arteriosclerosis was commonly found. It caused no obvious symptoms and no heart attacks or sudden death, but could account for some decreased heart contractility.
- The presence of an arrhythmia does not mean the dog has or will develop cardiomyopathy, but it may cause sudden death.

- There was a high incidence of cancer in the Salukis examined. A rare form, hemangiosarcoma, was found in 25% of the hearts. Clearly this incidence of cancer needs further investigation.

- Sudden death can often, but not always, be attributed to an arrhythmia or rupture of a hemangiosarcoma.
- Because congenital heart defects may cause death at an early age, the incidence in this group was low.
- Heart conditions can progress in severity with time.

Without the support of the generous individuals who have either allowed their dogs to be examined or offered their financial support, this would not have been possible. Thank you for your contributions.

Fig.7

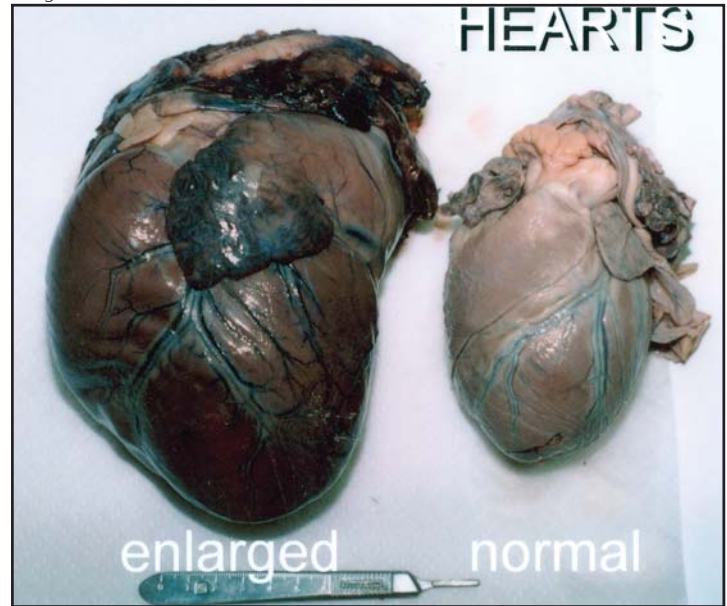


Fig 8

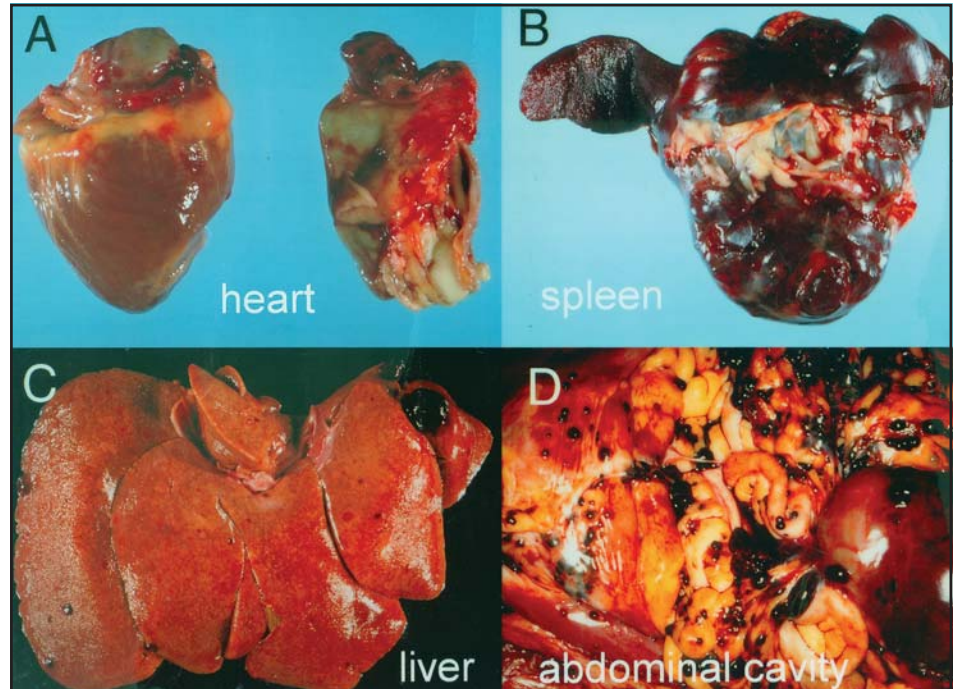


Fig. 9 Purkinje fiber necrosis, swelling and vacuolization; causes a conduction disturbance in the heart and the resulting arrhythmia can lead to sudden death

