

Salukis With Broken Hearts

Mary Dee Sist, DVM

As a veterinarian in private practice for 17 years, I have noted that the incidence of heart problems appears to be on the rise for dogs in general and Salukis in particular. It's unknown whether this is the result of genetic selection and line breeding in certain geographic areas or due to an increased awareness of heart problems on the part of owners, breeders and veterinarians. One thing is certain: we do not know enough about the heart of sighthounds, particularly the Saluki, even though current medical technology stands ready to help us.

It is devastating to lose a dog prematurely. I know from experience. My dear companion and first Saluki Bitch dropped dead with no warning signs at 8 years of age. She died of heart failure, specifically cardiomyopathy.

Cardiomyopathy is a term given to diseases of the heart muscle that occur without significant deformities in the heart valves or blood vessels. The two forms seen in dogs are dilated and hypertrophic. In the dilated form (DCM), there is progressive dilation or enlargement of the ventricles, which are the main pumping chambers of the heart. There is some increase in the heart muscle mass (hypertrophy) and loss of contractile function, or pumping ability. In the hypertrophic form (HCM), the heart muscle mass increases tremendously. The dilated form is far more commonly seen, and occurs predominately in young to middle-aged males of larger breeds. There is a high prevalence of cardiomyopathy in certain breeds.

The causes of cardiomyopathy remain unknown, though viral infections, nutritional deficiencies and genetic causes have been proposed. Treatment aims to adjust the mechanical function of the heart and/or the peripheral circulation to compensate as long as possible for the malfunctioning heart muscle. Early diagnosis is difficult without baseline data, as will be discussed later.

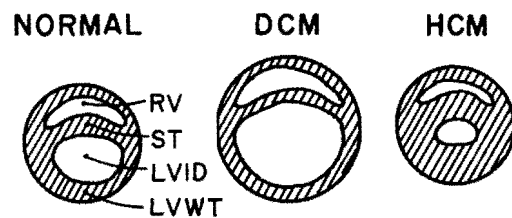
Cardiomyopathy is a certain and often unannounced killer. As the ongoing pathological muscle changes that cause cardiomyopathy take place, the dog's heart and body compensate for the poor myocardial function, or weakened pumping ability. In this compensatory phase the dog generally exhibits no signs or symptoms. As the disease advances, the dog may appear a bit sluggish or weak at times, and possibly have some weight loss. But the heart will eventually fail, causing sudden death due to arrhythmia or the classical signs of heart failure. These include some combination of lethargy, weakness, anorexia, weight loss, exercise intolerance, difficult breathing, soft cough, fainting or ascites, which is fluid accumulation in the abdominal area. These signs worsen with mild exertion.

Standard methods of diagnosing heart problems have their limitations in diagnosing cardiomyopathy when the dog is not yet in heart failure. A physical exam, including auscultation (listening to the heart), may show no abnormalities. A heart murmur will generally not be present unless there is also a problem with the heart valves. An arrhythmia, or change in the normal heart rhythm, may or may not be heard. On a radiograph, the heart may not be grossly enlarged; vascular and lung changes might not yet be present. An electrocardiogram (ECG) will show arrhythmias if they are present. But none of these diagnostic approaches targets cardiomyopathy in particular.

One new development offers a tool for the diagnosis of cardiomyopathy — the fairly recent use of ultrasound in veterinary medicine. Ultrasound examination of the heart, or echocardiography, is a non-invasive method of viewing and measuring the heart chambers, valves and muscle in motion as the heart beats. This makes it possible to evaluate cardiac dimensions and function.

In general, cardiologists evaluate the echocardiogram for "changes" from normal dog measurements. Echo changes in DCM include dilation of all cardiac chambers, with the left side of the heart more severely affected; reduced pumping power as evidenced by decreased contractility, and thinning of the interventricular septum and left ventricular free wall. In HCM, the interventricular septum and left ventricular free wall are very thick, or hypertrophied, with a normal to small left ventricular chamber size. Contractility may be normal to increased, and the left atrium is enlarged. These changes are shown in figure 1.

fig. 1 - Cross-sectional view through the ventricles of the heart



RV - right ventricle; ST - interventricular septum; LVID - left ventricular internal dimension; LVWT - left ventricular free wall

I had bred my bitch long before her untimely death, and was concerned that her condition could be inherited. To see if that was possible, I bred her daughter to a sister's son. The progeny of that breeding are now eight years old, have never been bred, and have no signs of problems. I had them "echoed," and they showed departures from the normal dog measurements, but no clear evidence of the HCM of which their grandmother had died. Were these changes significant?

This is not the conclusive evidence I sought. The problem lies in the fact that there is no echocardiographic baseline data on sighthounds — let alone for Salukis. The data establishing the "normal" dog measurements have been generated using a relatively small sampling of mongrel dogs. No breed-specific normals have been established to date.

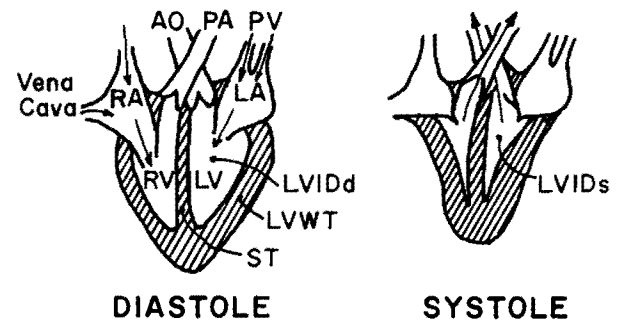
Sighthounds are unique, definitely different in both conformation and in some physiological respects from mongrel dogs. For example, the deep chest and more upright heart of sighthounds suggest that normal data may not apply. In addition, most sighthounds are athletes and it is documented that well-trained human athletes have cardiac "changes" outside the norm. In researching echocardiography normal data, I came across an interesting comment by veterinary cardiologist Dr. Chris Lombard in his article entitled "Normal Values of the Canine M-Mode Echocardiogram". "It is very likely," Lombard states, "that racing dogs, such as Greyhounds, with documented higher relative heart weights, will have greater cardiac dimension on comparative echocardiographic studies between breeds." He also suspects an age-induced hypertrophy, or thickening, of the left ventricular wall, which might be outside the normal range he generated.

If Lombard was correct in his suspicions about Greyhounds' departing from the norm, I wondered if I might assume such departures from the norm could also be expected in Salukis. Therefore, my Salukis who were outside the norm might be part of a different norm — one for sighthounds in general, or one specific to Salukis. It was clear that more data were required.

I was fortunate enough to find a cardiologist, Dr. Cathy Gaber at Michigan State University, who was interested in working with Salukis to try to establish a normal Saluki data-base. We echoed 20 largely older Salukis of both sexes, from a variety of lines, all of which had actively coursed for various periods of time. It was not inexpensive, so I was pleased that these Salukis owners were willing to invest the money and time to have their dog's heart echoed in order to help the breed. Since all the dogs were healthy, in good condition and under regular care from the owner's veterinarians, only an echocardiogram was performed by the cardiologist.

Echocardiographic examinations are made in a cross-sectional plane, as shown in figure 1, and in a longitudinal plane through the heart, as shown in figure 2. As the heart beats, the valves are seen in motion as they open and close, and their function is assessed. In diastole, blood flows into the heart (as indicated by the arrows) and the heart is relaxed. In systole, blood is pumped out the aorta to the body and out the pulmonary artery to the lungs, and the ventricles are contracted.

fig. 2 - Longitudinal view through the heart



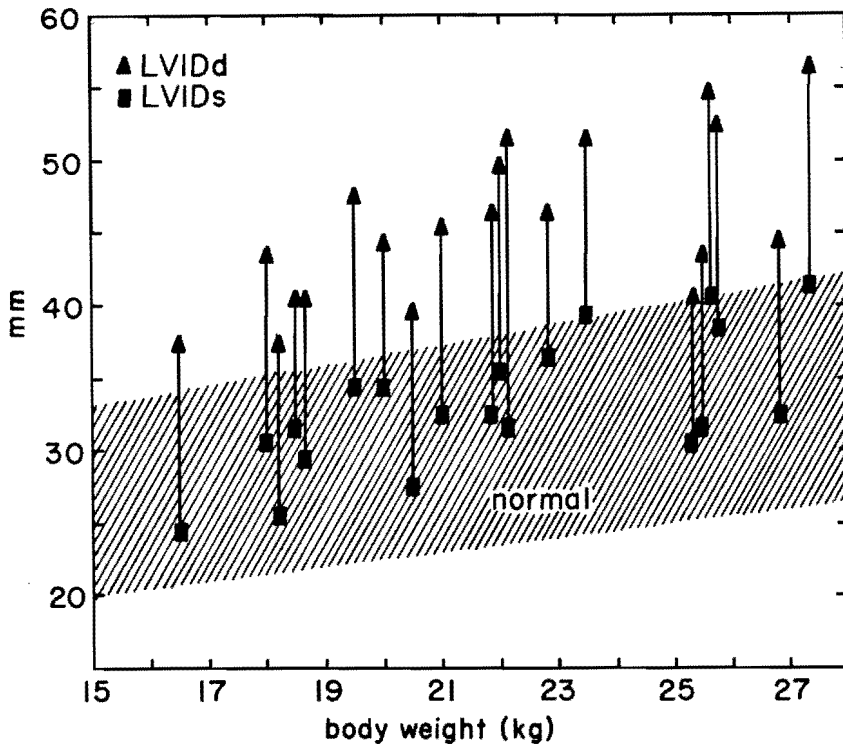
RV - right ventricle; RA - right atrium; AO - aorta; PA - pulmonary artery; PV - pulmonary veins; LA - left atrium; LV - left ventricle; LVIDd - left ventricular internal dimension in diastole; LVWT - left ventricular free wall thickness; ST - interventricular septal thickness; LVIDs - left ventricular internal dimension in systole

The most important measurements made during the examination include:

- LVID: Left ventricular internal dimension in diastole.
- LVIDs: Left ventricular internal dimension in systole.
- The difference between these indicates the pumping ability of the heart, or contractility.
- ST: Interventricular septal thickness.
- LVWT: Left ventricular free wall thickness.
- AOD: Aortic dimension at its base.
- LAs: Left atrial size.

Larger dogs have larger hearts. The accompanying two graphs show the echo measurements for the 20 Salukis plotted according to their body weights. Dr. Lombard's normals generated from 40 mongrel dogs are shown for comparison.

The first graph shows the LVIDd (▲) and the LVIDs (■) and the line connecting these two measurements shows the contractility, or pumping ability, for each Saluki. All the lines should be within the shaded normal area. Nearly all the Salukis have varying degrees of enlargement of the left ventricle when compared to the norm. At what degree is this hypertrophy pathological? What is normal for



graph 1 - M-mode echocardiographic measurements for 20 Salukis compared to "normals"

Salukis in general and for older Salukis in particular? A few Salukis had longer lines and a few had shorter lines, but most are within the expected normal contractility range. For these few is this an early indication of myocardial problems (compensation or weakening)?

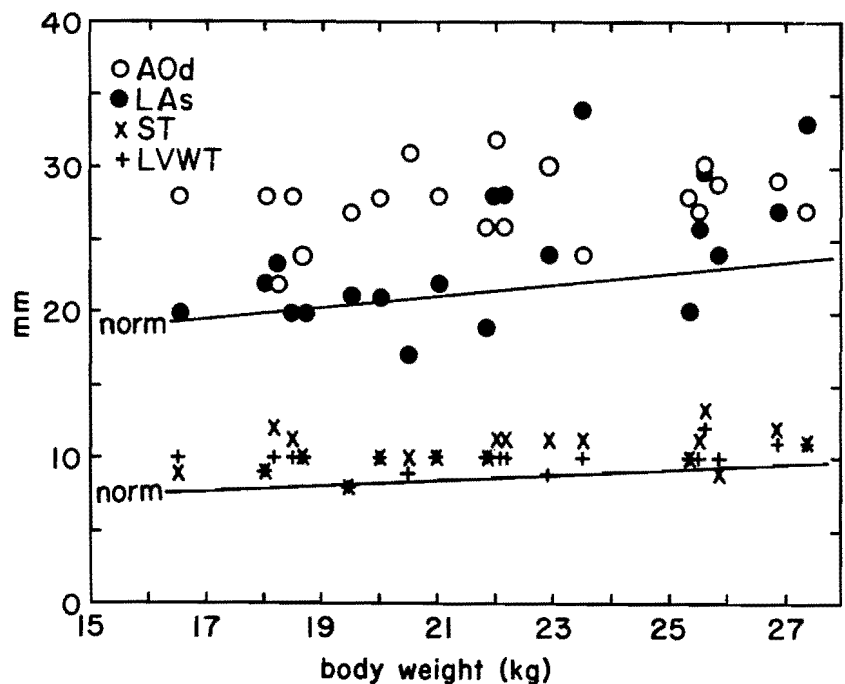
The second graph shows the size of the aorta (o AOD) and the left atrium (— LAs) for each Saluki. As indicated by the single solid "normal" line, these should be approximately the same size (LAs/AOD ratio should be 0.8 to 1.2). All the points should be near the solid "normal" line. Most of the Salukis have enlarged aortas. The aorta dilates when there is a stenosis, or abnormal narrowing, but the chances of this many dogs in one sample having an aortic deformity are nil. Hypertension can also cause aortic dilation. Are these dogs hypertensive? There is no reliable non-invasive way to measure arterial blood pressure in dogs. Could the large aortic dimensions be artifactual due to the more upright position of a sighthound heart in a deep chest? Furthermore, two Salukis have very enlarged left atria. Is this a sign that their hearts are failing?

The second graph also shows the size of the ST(x) and LVWT(+) for each Saluki. The slight enlargement are consistent with hypertrophy, but these are not a great deal larger than the norm.

Overall, it's clear that while this initial echocardiography study in Salukis was intended to answer few questions, it raised more questions than it answered.

One sighthound breed has been the subject of fairly extensive heart research — the Greyhound. A review of the research points in some interesting directions for those of us concerned about the Saluki. Schneider, et al, in "Comparative Observations of the Heart of Mongrel and Greyhound Dogs" have this to say: "Through 3,000 years of selective breeding and training, this animal (the Greyhound) now possesses a heart that is an outstanding example of true physiological work hypertrophy." Schneider documented that Greyhound hearts are over 50% larger than mongrel hearts in relation to body weight. This is also the case with the Thoroughbred horse compared with non-racing horses. This study also showed that Greyhounds had significantly higher blood pressure readings than mongrel dogs. Moreover, it states that "there is no indication that enlargement constitutes or predisposes disease" and draws a correlation to the "still unsolved problem of the 'athletic heart' and its questionable predisposition to disease."

Cox, et al, in his "Comparison of Arterial Hemodynamics in the Mongrel Dog and the Racing Greyhound" asserts that "Greyhounds have a naturally occurring significantly higher mean arterial pressure and greater cardiac output with a lower total peripheral resistance compared to the mongrel," and "that venous plasma renin activity is significantly higher in the mongrel than in the racing Greyhound, which might indicate how the Greyhound's physiology has adapted to protect it from the untoward effects of their higher blood pressure." This



graph 2 - M-mode echocardiographic measurements for 20 Salukis compared to "normals"

work also showed that the Greyhound's aorta and other vessels were more compliant. "In Greyhounds, that have been an established coursing breed for 2800 years, hereditary factors have resulted in an arterial system adapted to the large ventricular ejection. These studies indicate that the Greyhound is a breed with distinctive hemodynamic characteristics (including high cardiac output and blood pressure) which set it apart from other animals of the same species." Cox's results were similar for dogs that had undergone training and had been recently raced and for "bench" dogs that had never been trained or raced, as well as for "retired" dogs. In addition, puppy heart weight to body weight ratios were significantly larger for Greyhounds than in Coonhound pups. Cox further states that the "elevated cardiac output and arterial pressure in young Greyhounds suggest that this animal has characteristics similar to the early phase of essential hypertension." Thickening (hypertrophy) of the left ventricular wall is an adaptive response of the heart to hypertension.

To sum up heart research on Greyhounds in contrast to mongrels, studies have shown they exhibit the following characteristics:

1. Large hearts with hypertrophy of the left ventricle.
2. Higher arterial blood pressure (hypertension) and that hypertension can cause adaptive hypertrophy.
3. Greater cardiac output.
4. Lower total peripheral resistance — the aorta and other vessels are more compliant.

Clearly Greyhounds differ from mongrel baseline data, and it would seem that these differences could be adaptive rather than suggestive of potential heart problems. But is the same true for Salukis? There simply isn't enough baseline data to say, as the 20 Salukis echoed in this study constitutes a sample too small upon which to draw conclusions. What's needed is a much larger sample, the accumulation of data from echoing at least 40 Salukis (comparative to Lombard's study of 40 mongrel dogs). We also need to repeat the echocardiograms on the 20 original Salukis to see what changes occur over time, and to see if any develop HCM or DCM.

Research requires time and money — and generates no income. Yet it must be funded. Ultrasound equipment is expensive, and the services of a trained cardiologist skilled in echocardiography come dearly in veterinary medicine. One reason why research on Greyhounds has been done is that race track reject Greyhounds are, sadly, very cheap and numerous. Fortunately for the breed, our Salukis are not, but those of us who own them then have the responsibility to do what we can to make research accessible to the breed.

How can you help? First, by donating funds to schools of veterinary medicine where pertinent research is being done. You can also search out a trained cardiologist who will perform echocardiograms on your Salukis and who is also willing to follow a strictly outlined examination and measuring procedure to reduce the variances that can occur when different cardiologists employ slightly different techniques of evaluation. By sharing our findings, cardiologists will have the kind of sample required to establish baseline data and to identify Salukis who have early indications of cardiomyopathy. You have an opportunity to take part in funding and developing the first known breed-specific normals, which could go far in helping to ensure the future of the Saluki.

Feel free to contact me if you wish to participate:
Mary Dee Sist, DVM / 1629 Meech RD. / Williamston, MI. 48895.

**ASA South Central TSE
September 8, 1991**

**Des Moines Kennel Club
Des Moines, IA.**

**Saluki Judge: Kent Delaney
Chairman: Sara Winsted**

**ASA Pacific Southwest TSE
September 15, 1991**

**Sir Francis Drake Kennel Club
San Rafael, CA.**

**Saluki Judge: Marvin Crandahl
Chairman: Kim Morrison Anselmo**

**ASA Atlantic Northeast TSE
September 28, 1991**

**Onondaga Kennel Club
Saluki Judge: Betty Sandberg
Chairman: Jean Faulkner**

UPCOMING!

**ASA Pacific Southwest TSE
January 5, 1992**

**Kennel Club of Palm Springs
Palm Springs, CA
Saluki Judge: Dale Wright
Chairman: Sharon Kinney**